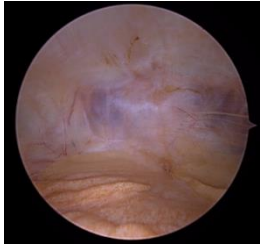


Kniegelenksarthroskopie – Standardisierter Rundgang und Bildgebung

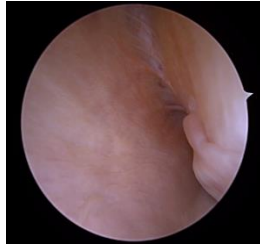Standard Zugänge:

anterolaterales und anteromediales Portal

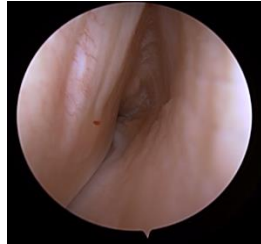Optional: hohes anterolaterales, posterolaterales und posteromediales Portal



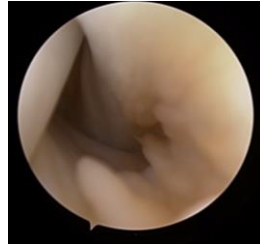
Suprapatellarer
Recessus



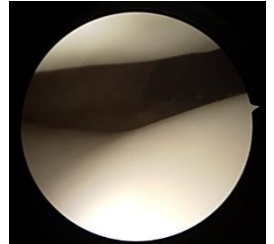
Medialer Recessus



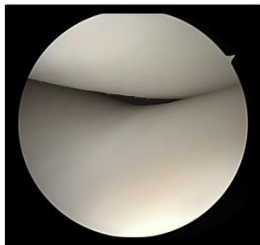Lateraler Recessus



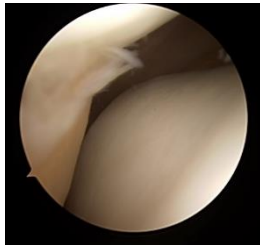
Fossa poplitea



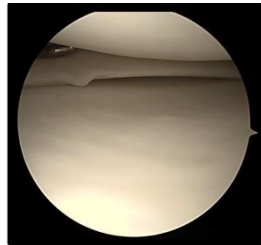
Patellofemorales
gelenk



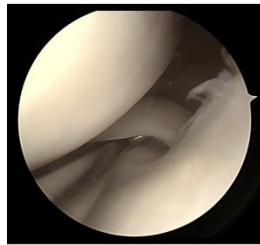
Patellatracking
0-90°



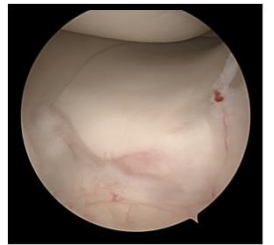
Plica
mediopatellaris



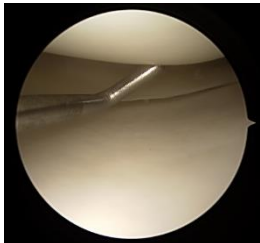
Innenmeniskus-
hinterhorn



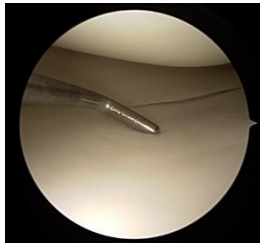
Innenmeniskus-
hinterhornwurzel



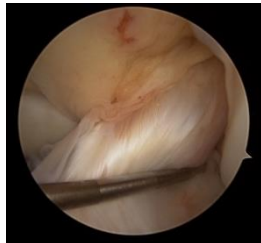Innenmeniskus-
vorderhornwurzel



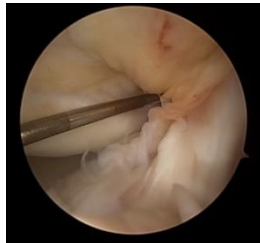Knorpel medialer
Femurkondylus



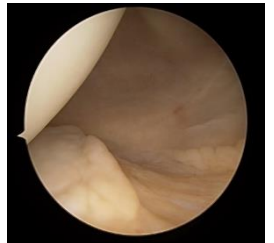
Knorpel mediales
Tibiaplateau



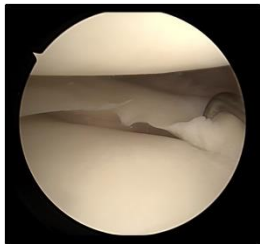
Vorderes
Kreuzband



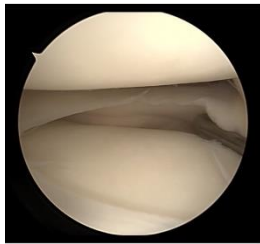
Hinteres
Kreuzband



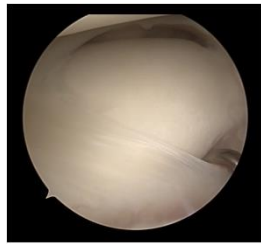
Posteromedialer
Recessus



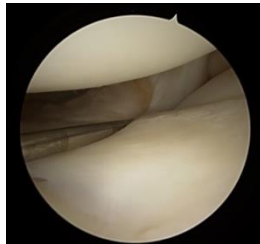
Aussenmeniskus-
hinterhorn



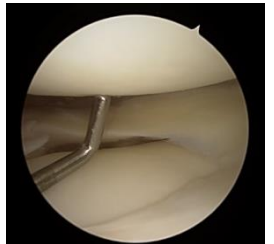
Aussenmeniskus-
hinterhornwurzel



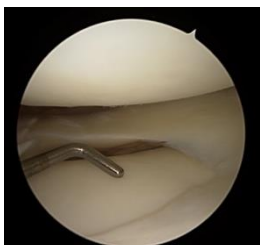
Aussenmeniskus-
vorderhornwurzel



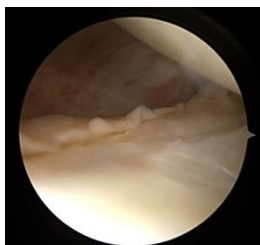
Popliteussehne



Knorpel lateraler
Femurkondylus



Knorpel laterales
Tibiaplateau



Posterolateraler
Recessus

Optional:
Posteromedialer
Zugang

